



Increasing our understanding of rotavirus-induced central nervous system manifestations

Jon Soo Kim, MD, PhD

Department of Pediatrics, Chungbuk National University Hospital, Cheongju, Korea

Key message

- Diverse clinicoradiological features of central nervous system (CNS) complications in rotavirus infection can be identified with the rapid and wide use of various brain magnetic resonance imaging protocols.
- An increased understanding of the various pathophysiological mechanisms of rotavirus-induced CNS manifestations will enable precise management in the future.

Introduction

Rotavirus and norovirus are the most common causative agents of acute gastroenteritis in children aged <5 years worldwide.¹⁾ Children with rotavirus infection of the small intestine may experience diarrhea, vomiting, and fever. However, it is generally self-limiting and lasts only a few days.²⁾ Since the introduction of rotavirus vaccines, the burden of the disease has reduced significantly; however, rotavirus remains a common cause of hospitalization.³⁾ Rotavirus is known to cause systemic infection according to recent extraintestinal spread findings.⁴⁾ Rotavirus infection shows a wide spectrum of central nervous system (CNS) manifestations, including benign convulsions with mild gastroenteritis (CwG), acute meningoencephalitis, white matter injuries, and lethal encephalitis/encephalopathies.^{4,5)} However, although it has not yet been clearly identified as a risk factor for rotavirus-related CNS complications, regional or racial differences are suspected, as it is reported more often in East Asia than in Europe or the United States.⁶⁾

CwG is the most commonly encountered CNS complication, occurring in previously healthy infants and children aged 6 months to 3 years.⁷⁾ It is characterized by afebrile brief tonic-clonic seizures between the 1st and 5th sick days of gastroenteritis, tending to occur repetitively over several days. However, the findings of interictal electroencephalography, cerebrospinal fluid (CSF), and brain magnetic resonance imaging (MRI) examinations are mostly normal.^{1,7)} Despite clustered seizures, long-term anti-seizure medication is usually not required because of the

good prognosis.⁷⁾ In addition to CwG, diverse clinicoradiological features related to rotavirus infection in the brain have been reported, as various brain MRI protocols, such as fluid attenuated inversion recovery and diffusion-weighted imaging, have been widely and early applied in clinical settings.⁵⁾ Rotavirus-induced CNS complications primarily involve acute encephalopathy with transient and reversible changes rather than acute encephalitis with destructive lesions on MRI. These include white matter injuries in neonates, mild encephalopathy with a reversible splenic lesion, acute encephalopathy with biphasic seizures and reduced diffusion, and posterior reversible encephalopathy syndrome.^{8–10)} Despite many reports of rotavirus infection and CNS manifestations, definite and consistent evidence of its pathophysiological mechanisms is lacking.^{2,11)}

Based on the author's arguments, the following hypotheses were proposed (Fig. 1).⁵⁾ First, CNS-driven symptoms such as vomiting, sickness, loss of appetite, and malaise are considered brain-gut communication in rotavirus infection.^{2,11)} This includes activating the vagal nerves that project to regions of the brain via enterotoxin nonstructural viral protein 4-dependent 5-hydroxytryptamine release.¹¹⁾ Second, previously described CNS complications are explained as direct CNS effects, although rotavirus antigen and ribonucleic acid are rarely detected in the CSF.⁵⁾ Potential mechanisms by which the pathogen causes these diverse CNS complications are: (1) direct viral invasion into the CNS; (2) CNS entry of deleterious brain-damaging mediators; and (3) CNS entry of activated circulating leukocytes.⁵⁾ The most likely mechanism is that the blood-borne rotavirus enters the brain via disrupted and increased vascular permeability of the blood-brain barrier (BBB); thus, the direct viral infection of neuronal cells induces cytopathic results.^{2,11)} Various circulating mediators produced during rotavirus infection can damage BBB integrity and induce hypothalamic dysregulation. According to several recent studies, inflammatory cytokines and reactive oxygen species levels are significantly elevated in the CSF.^{2,5)} Finally, systemic inflammation-induced circulating leukocytes can transmute across the BBB and injure neuronal cells.

Although the burden of rotavirus infection has been reduced

Corresponding author: Jon Soo Kim, MD, PhD, Division of Pediatric Neurology, Department of Pediatrics, Chungbuk National University Hospital, 776 Sunhwan-1-ro, Seowon-gu, Cheongju 28644, Korea
✉ Email: pedkjs79@naver.com, <https://orcid.org/0000-0003-2586-1942>
Received: 6 March 2022, Revised: 4 April 2022, Accepted: 6 April 2022

This is an open-access article distributed under the terms of the Creative Commons Attribution Non-Commercial License (<http://creativecommons.org/licenses/by-nc/4.0/>) which permits unrestricted non-commercial use, distribution, and reproduction in any medium, provided the original work is properly cited.
Copyright © 2022 by The Korean Pediatric Society

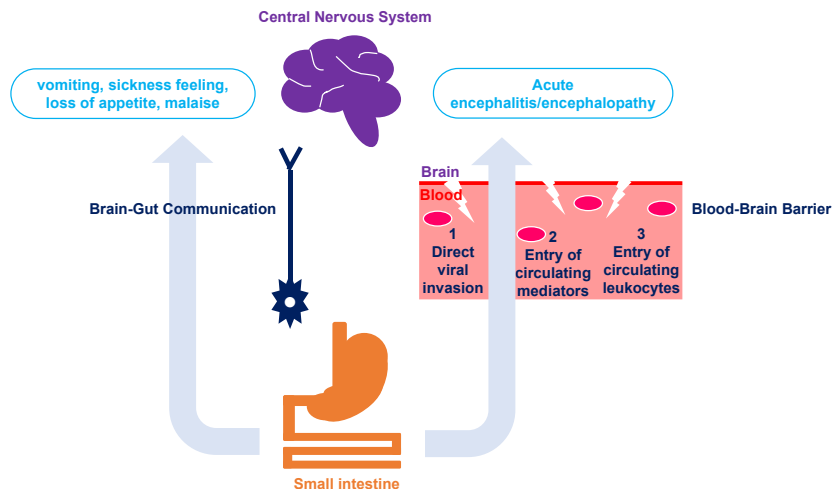


Fig. 1. Schematic illustration of possible mechanisms by which rotavirus infection can cause central nervous system manifestation.

owing to the widespread introduction of vaccines, rotavirus-induced CNS complications remain important. Diverse clinico-radiological features can be identified using brain imaging in the early stages of neurological symptoms. This may be attributed to the gut-brain communication as well as direct CNS entry of various mediators, immune cells, and even the virus itself. An increased understanding of rotavirus-induced CNS manifestations will enable more precise management in the future.

See the article “Rotavirus infection-associated central nervous system complications: clinico-radiological features and potential mechanisms” via <https://doi.org/10.3345/cep.2021.01333>.

Footnotes

Conflict of interest: No potential conflict of interest relevant to this article was reported.

ORCID:

Jon Soo Kim  <https://orcid.org/0000-0003-2586-1942>

References

1. Kang B, Kwon YS. Benign convulsion with mild gastroenteritis. *Clin Exp Pediatr* 2014;57:304-9.
2. Hellyasz A, Hagbom M. Understanding the central nervous system symp-

tom of rotavirus: a qualitative review. *Viruses* 2021;13:658.

3. Lee YS, Kim DH, Ha DJ, Kwon YS. Comparison of the demographics and ratio of rotavirus associated benign convulsions with mild gastroenteritis to rotavirus gastroenteritis before and after rotavirus vaccination over a period of 20 years. *Ann Child Neurol* 2021;29:75-82.
4. Jalilvand S, Marashi SM, Tafakhori A, Shoja Z. Extraintestinal involvement of rotavirus infection in children. *Arch Iran Med* 2015;18:604-5.
5. Lee KY. Rotavirus infection-associated central nervous system complications: clinico-radiological features and potential mechanisms. *Clin Exp Pediatr* 2022 Feb 7. <https://doi.org/10.3345/cep.2021.01333>. [Epub].
6. Verrotti A, Nanni G, Agostinelli S, Parisi P, Capovilla G, Beccaria F, et al. Benign convulsions associated with mild gastroenteritis: a multicenter clinical study. *Epilepsy Res* 2011;93:107-14.
7. Kim YO. Benign convulsions with mild gastroenteritis. *Ann Child Neurol* 2020;28:2-7.
8. Karampatsas K, Spyridou C, Morrison IR, Tong CY, Prendergast AJ. Rotavirus-associated mild encephalopathy with a reversible splenic lesion (MERS)—case report and review of the literature. *BMC Infect Dis* 2015;15:446.
9. Yeom JS, Park C. White matter injury following rotavirus infection in neonates: new aspects to a forgotten entity, 'fifth day fits'? *Clin Exp Pediatr* 2016;59:285-91.
10. Lee DJ, Kim JS. Rotavirus infection-associated posterior reversible encephalopathy syndrome. *Ann Child Neurol* 2019;27:60-2.
11. Crawford SE, Ramani S, Tate JE, Parashar UD, Svensson L, Hagbom M, et al. Rotavirus infection. *Nat Rev Dis Primers* 2017;3:17083.

How to cite this article: Kim JS. Increasing our understanding of rotavirus-induced central nervous system manifestations. *Clin Exp Pediatr* 2022;65:536-7. <https://doi.org/10.3345/cep.2022.00395>